

Amyand's hernia - A rare case report and the appropriate approach to its management

Niranjan Moharana, Pradipta Kumar Das, Sudhir Kumar Panigrahi, Amaresh Mishra

Department of General Surgery, Kalinga Institute of Medical Sciences, Bhubaneswar, Odisha, India.

Abstract

A 54 years male admitted with a reducible right groin swelling of 8 months duration which is irreducible since 10 days with occasional mild dragging pain in the swelling. Clinical examination established a diagnosis of irreducible omentocele with a bowel loop as a component due to the variegated consistency of the swelling. Intraoperatively the hernia sac was found to contain greater omentum, caecum, terminal ileum and a grossly elongated non inflamed appendix. Then the diagnosis was certain to be right sided Amyand's hernia. Releasing adhesions to the sac, appendectomy, reduction of contents, distal sac excision and hernioplasty using prolene mesh was done. Patient is doing well after 18 months of follow up. Hence awareness of this rare entity, early recognition and adoption of judicious surgical technique are the keys to an optimised outcome in the management of an Amyand's hernia.

Key words: Appendix, inguinal hernia, Amyand's hernia, appendectomy, hernia repair.

Introduction

The term Amyand's hernia refers to the finding of an appendix within an inguinal hernia sac. Claudius Amyand was a French born English surgeon and a Sargent surgeon to King George I and II. In 1735, he successfully operated a perforated appendix in a 11year boy admitted for right sided inguinal hernia with fecal fistula^[1]. The incidence of Amyand's hernia is about 1% of inguinal hernias, commonly seen in males as right sided indirect inguinal hernia while 0.07 to 0.13% of the inguinal hernias are found with an inflamed appendix^[2]. The presence of appendix within the femoral hernia sac is called Garengéot's hernia as described by the French surgeon Garengéot. Left sided Amyand's hernia are very rare with a total of 15 cases reported so far and are thought to be due to situs inversus, malrotation, a mobile caecum or an excessively long appendix^[3]. Appendicular perforation and periappendicular abscess formation in an Amyand's hernia are extremely rare occurrences. Appendix has also been reported to be found in umbilical hernia, obturator hernia, spigelian hernia, incisional hernia, diaphragmatic hernia and laparoscopic port site hernia. The cause of acute appendicitis in Amyand's

hernia is thought to be extrinsic compression at neck rather than usual intraluminal obstruction^[4]. Appendix in an Amyand's hernia is prone for trauma and possibility of adhesions within the sac^[5]. Factors like sudden raised intraabdominal pressure and contraction of abdominal muscles may compress the appendix against the neck interfering with its blood flow with resultant appendicitis, perforation and peritonitis.

Clinical presentation commonly varies from a asymptomatic to mild intermittent discomfort or pain, fever, vomiting, distension of the abdomen in a inguinal swelling and hence usually escapes the preoperative diagnosis of Amyand's hernia, rather such presentations are considered as an incarcerated or strangulated inguinal hernia^[6]. Preoperative ultrasound and CT scan of the abdomen and pelvis helps in confirming the diagnosis^[7,8]. Ultrasound reveals a thickened blind tubular structure in connection with caecum inside the hernia sac and CT scan locates the appendix in the inguinal region.

Differential diagnosis includes strangulated omentocele or enterocele, inguinal adenitis, undescended testis, epididymo-orchitis, hydrocele,

Address for Correspondence

Prof. (Dr) Sudhir Kumar Panigrahi

Flat - D-201, Aradhana Palace, Nandan Vihar , Kalarahanga, Bhubaneswar - 751024 Odisha

E -mail: drsudhir147@gmail.com

hemorrhage into a testicular tumor, chronic scrotal sinus or necrotising fasciitis of groin or scrotum. The staging and management of Amyand's hernia is based on Lasanoff and Basson's classification^[9].

Lasanoff and Basson's classification for staging and management of Amyand's hernia:

Stage of hernia	1	2	3	4
Salient features	Normal appendix	Acute appendicitis localized in the sac	Acute appendicitis, peritonitis	Acute appendicitis, other abdominal pathology
Surgical management	Reduction or appendectomy (depending on age), mesh hernioplasty	Appendectomy through hernia, endogenous repair	Appendectomy through laparotomy, endogenous repair	Appendectomy, diagnostic workup and other procedures as appropriate

Another simple classification of Amyand's hernia is by Fernando et al., based on the degree of inflammation seen in the appendix, namely Type A (non-inflamed), Type B (inflamed) and Type C (perforated). Type A hernia are the most frequent accounting for approximately 90% of cases and are encountered as an unexpected and incidental finding at elective inguinal hernia repair.

Case report

A 54 years gentleman, farmer by occupation, admitted with irreducible right sided groin swelling with intermittent dull aching pain for 10 days. He does not give history of fever, vomiting, distension of abdomen or an altered bowel and bladder function. He had reducible right groin swelling since 8 months. No associated co-morbid conditions like chronic cough, constipation, diabetes mellitus, hypertension or surgery in the past. On examination a right inguinal swelling of about 12cm length and 8cm breadth, which was of variegated consistency, nontender, noninflamed and irreducible. With a provisional diagnosis of omentocele with a loop of unobstructed bowel as the content of the sac, he was posted for surgery. Intraoperative findings revealed entrapped omentum occupying almost entire sac with caecum and a noninflamed, excessively elongated appendix of about 18cm length with distal third adhered to the sac on posterior aspect (Figure 1 and 2). It was then diagnosed as an Amyand's hernia. Adhesions were released, appendectomy and omentectomy distal to the neck done. Hernioplasty using prolene mesh performed. The patient was discharged on 4th postoperative day. Biopsy of the excised appendix revealed a nonulcerated healthy looking mucosa without any luminal exudate and a well preserved architecture of other layers of the appendix. The patient was found free of complaints or complications relating to the surgery at 18 months of follow up.

Intraoperative Photos

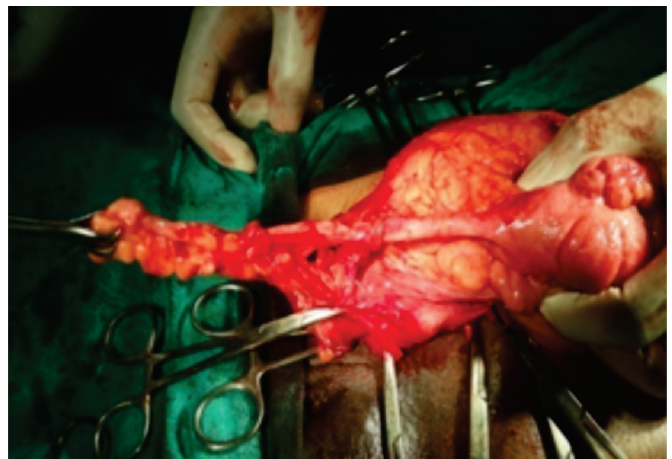


Figure 1. Caecum with elongated appendix after releasing the adhesion of its tip to the hernia sac

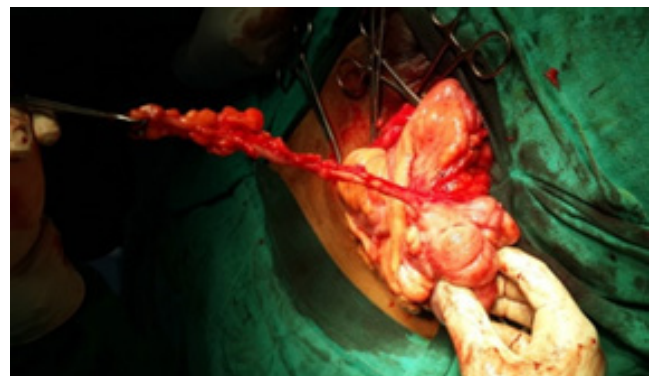


Figure 2. Dissected appendix prior to appendectomy

Discussion

Amyand's hernia is a rare occurrence and is mostly diagnosed intraoperatively. Its presentation varies from asymptomatic to that of an obstructed or strangulated hernia or rarely as groin or scrotal cellulitis or fecal fistula especially in undiagnosed neglected cases. The significance of prior knowledge of this entity amongst surgeons will surely help in preoperative diagnosis and planning the

management in regards to removal of the appendix and decision at mesh repair of the hernia. Prophylactic appendectomy is not recommended for Amyand's hernia with noninflamed appendix. However in younger patients with high chances of future attacks and elongated curved appendix that runs a high risk of obstructive appendicitis, appendectomy is preferred. Mesh repair of the hernia can be done in normal or mildly congested appendix, but avoided for inflamed, gangrenous or perforated appendicitis in view of wound infection, sepsis, fistula formation, recurrence and higher chance of mesh explantation. A case series of Amyand's hernia in three patients managed by TAPP (transabdominal preperitoneal) mesh repair without appendectomy when the appendix looks normal or mildly congested is a preferred option. However the recommended treatment of an inflamed appendix is by open or laparoscopic appendectomy followed by an open suture repair of the right inguinal hernia via a groin incision^[10].

Conclusion

The knowledge of the rare Amyand's hernia helps the surgeon in preoperative diagnosis in suspicious cases with the help of ultrasound and CT scan and thus correctly preparing and planning the management of the hernia. Decision regarding removal of the appendix and mesh repair of the hernia is to a great extent individualized based on the age of the patient, size and shape of the appendix and presence of inflammation or infection in the appendix.

References

1. Amyand C. "Of an inguinal rupture, with a pin in the appendix caeci incrustrated with stone, and some observations on wound in the guts," *Philosophical Transactions of the Royal Society London* 1736; 39:329342.
2. Constantine S. Review of literature- Computed Tomography Appearances of Amyand Hernia. *J Comput Assist Tomogr* 2009; 33:359-62.
3. Bakhshi GD, Bhandarwar AH, Govila AA. Acute appendicitis in left scrotum. *Indian Journal of Gastroenterology* 2004; 23(5):195.
4. Singal R, Mittal A, Gupta A. An incarcerated appendix: report of three cases and a review of the literature. *Hernia* 2010; 14:26.
5. Abu-Dalu J, Urca I. Incarcerated inguinal hernia with a perforated appendix and periappendicular abscess. *Dis Colon Rectum* 1972; 15:464-65.
6. Priego P, Lobo E, Moreno I, Sánchez-Picot S, Gil Olarte MA, Alonso N, Fresneda V. Acute appendicitis in an incarcerated crural hernia: analysis of our experience. *Rev Esp Enferm Dig* 2005; 97: 70715.
7. Akfirat M, Kazez A, Serhatlio_glu S. Preoperative sonographic diagnosis of sliding appendiceal inguinal hernia. *J Clin Ultrasound* 1999; 27: 156-8.
8. Luchs JS, Halpern D, Katz DS. Amyand's hernia: prospective CT diagnosis. *J Comput Assist Tomogr* 2000;24: 884-6.
9. Losanoff JE, Basson MD. Amyand hernia: a classification to improve management. *Hernia J Hernias Abdom Wall Surg* 2008; 12: 325-6.
10. Tycast JF, Kumpf AL, Schwartz TL, Coln CE. Amyand's hernia: a case report describing laparoscopic repair in a pediatric patient. *J Pediatr Surg*.2008; 43(11):2112-4.

Conflict of interest: **Nil**

Source of funding: **Nil**

Date received: January 14th 2016

Date accepted: May 4th 2016